



PATIENT

Miles Allocco

SPECIES

Canine

BREED

Shih Tzu

SEX

Male Neutered

AGE

14.8 years

WEIGHT

12.52lbs

INTERPRETED BY

Maggie Machen Lamy,
DVM, DACVIM
(Cardiology)

IMAGING PERFORMED BY

Striano-Kaplan, DVM

HOSPITAL NAME

Ramsey Veterinary
Hospital

REFERRING VET

Dr. Striano-Kaplan

INVOICE

46552

DATE

1/23/26

PRESENTING CLINICAL SIGNS

History: Recheck echo. Grade 4-5/6 heart murmur. Doing well. Diabetes Mellitus.
-Current medications: Vetmedin 1.25mg tab 1.5 t BID, Ondansetron 4mg tab 1 t BID, Gabapentin 100mg PRN BID, Visbiome SID, Cobalaquin EOD, LRS 50 ml EOD, Vetsulin 5-6 units BID (depending on what dipstick says), Cerenia 24 mg tab 1/2tsid PRN, Cyclosporine TID OU, Tacrolimus TID OU.
-Pertinent previous echo findings (5/2025 MML): CVD b1. Mild to moderate MR, mild LAE. LA: 1.9, LV: 3.0. Continue Pimobendan.

ECHOCARDIOGRAM FINDINGS

Limited right-sided 2D, m-mode, color flow and doppler imaging is available. Mild diffuse thickening of mitral valve leaflets with mild prolapse into the left atrial lumen. Mild to moderate eccentric mitral regurgitation with mild left atrial dilation (subjective). Normal LV diameter with adequate myocardial function. The tricuspid valve appears normal with no tricuspid regurgitation. Normal right atrial and ventricular diameter and morphology indicating no overt evidence of pulmonary arterial hypertension. The pulmonic and aortic valves are normal in morphology and mobility. Normal pulmonic outflow velocity with laminar flow. No obvious aortic or pulmonic insufficiency. No pericardial or pleural effusion noted. No obvious cardiac masses.

CARDIAC CHART

CANINE CARDIAC PARAMETERS	MR VMAX (m/s)	TR VMAX (m/s)	LA/AO (Boon method)	LA/AO (Heart Base; Swe)	FS (%)	EF (%)	EPSS (cm)
NORMAL PARAMETER	4.5-5.5	<2.7	1.3	<1.6	28-40	40-100	<0.6
PATIENT	NM	NA	NM	NM	31	61	0.2
CANINE CARDIAC PARAMETERS	HR (BPM)	AV VMAX (m/s)	PV MAX (m/s)	BODY WEIGHT (kg)	LA 2D short axis Base view (cm)	LVIDd Avg; 2D and m-mode short axis (cm)	LVIDs Avg; 2D and m-mode short axis (cm)
NORMAL PARAMETER	50-100	0.7-1.7	0.7-1.6	BELOW	BELOW	BELOW	BELOW
PATIENT	NM	NM	0.5	5.7	NM	2.5	1.7
*Normal chamber parameters expressed as a mean value (SD)				3	1.27 (5.3)	2.46 (2.46)	1.36 (5.5)
BODY WEIGHT DEPENDENT PARAMETERS				5	1.40 (4.5)	2.74 (5.2)	1.60 (4.7)
*Note: All measurements based upon multi-modal images and methods. An average value is reported.				10	1.50 (3.8)	3.27 (3.5)	2.06 (3.1)
				15	1.83 (2.0)	3.71 (2.4)	2.43 (2.1)
				20	2.02 (1.9)	4.14 (2.2)	2.80 (2.0)
				25	2.18 (2.4)	4.48 (2.9)	3.10 (2.5)
				30	2.33 (3.3)	4.83 (3.9)	3.39 (3.4)
				35	2.48 (4.3)	5.17 (5.0)	3.69 (4.5)
				40	2.62 (5.2)	5.48 (6.1)	3.96 (5.4)
				50	2.88 (7.1)	6.07 (8.3)	4.46 (7.4)

INTERPRETATION OF THE FINDINGS & FURTHER RECOMMENDATIONS

Chronic degenerative valve disease persists with evidence of stability. Mild to moderate mitral regurgitation is unchanged, with stable chamber dimensions. A persistent lack of atrial or ventricular enlargement indicates the current risk for complication remains low. It is important to note that this is not a complete image set, and additional abnormalities may have been missed.



PATIENT

Miles Allocco

SPECIES

Canine

BREED

Shih Tzu

SEX

Male Neutered

AGE

14.8 years

WEIGHT

12.52lbs

INTERPRETED BY

Maggie Machen Lamy,
DVM, DACVIM
(Cardiology)

IMAGING PERFORMED BY

Striano-Kaplan, DVM

HOSPITAL NAME

Ramsey Veterinary
Hospital

REFERRING VET

Dr. Striano-Kaplan

INVOICE

46552

DATE

1/23/26

Given these findings, it is likely reasonable to Pimobendan going forward; however, stable mild disease across serial exams may warrant discontinuation in the future. While a lack of significant progression is certainly a good sign, continued monitoring is advised lifelong.

Omega fatty acid supplementation and mild salt restriction may be of some long-term benefit. Monitor for development of a cough, labored breathing, exercise intolerance or collapse episodes.

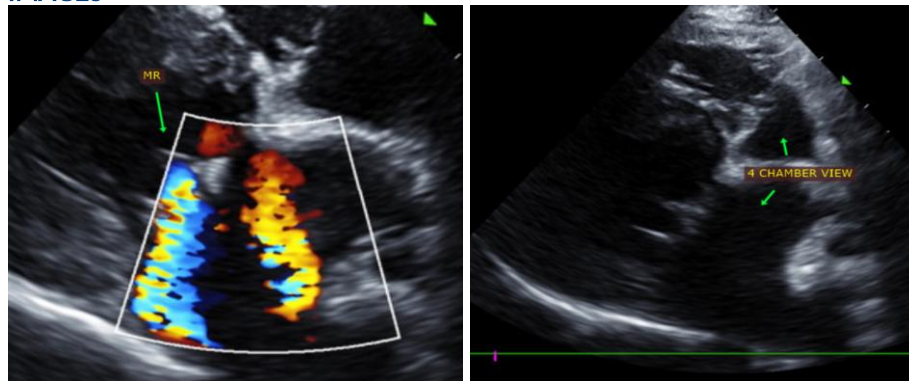
Anesthetic risk is considered mild if needed. Cardiac protective drug choices (opioid/benzodiazepine premedication, propofol or alfaxalone induction, isoflurane gas) are recommended. Pre-oxygenate for 5-10 minutes prior to induction. Monitor for arrhythmias, hypotension, and hypoxia both intra and post-operatively and intervene as necessary. Mild IV fluid restriction is recommended to avoid fluid overload. Avoid heart rate stimulating drugs such as atropine unless clinically indicated.

PLAN

Continue Pimobendan 0.3mg/kg PO q12h.

Recommend conservative monitoring with a recheck echocardiogram in 6-9 months, sooner if any development of clinical signs in the interim.

IMAGES



The information and recommendations provided are based on the images presented by the referring veterinarian. No evaluation can be communicated regarding pathology that was not visible in the image/video clips provided.

Thank you for this referral. This report was generated using transcription software, and minor dictation errors may be present. If the clinical or image interpretation does not parallel your findings or if I can be of any further assistance, please contact me.

Maggie Machen Lamy, DVM
Diplomate of the American College of Veterinary Internal Medicine (Cardiology)
info@sonopath.com